

7-1-2013

Is adrenalectomy necessary during unilateral nephrectomy for Wilms Tumor? A report from the Children's Oncology Group.

Kathleen Kieran

James R Anderson

Jeffrey S Dome
George Washington University

Peter F Ehrlich

Michael L Ritchey

See next page for additional authors

Follow this and additional works at: https://hsrc.himmelfarb.gwu.edu/smhs_peds_facpubs

 Part of the [Pediatrics Commons](#), and the [Surgery Commons](#)

APA Citation

Kieran, K., Anderson, J., Dome, J., Ehrlich, P., Ritchey, M., Shamberger, R., Perlman, E., Green, D., & Davidoff, A. (2013). Is adrenalectomy necessary during unilateral nephrectomy for Wilms Tumor? A report from the Children's Oncology Group.. *Journal of pediatric surgery*, 48 (7). <http://dx.doi.org/10.1016/j.jpedsurg.2013.04.019>

This Journal Article is brought to you for free and open access by the Pediatrics at Health Sciences Research Commons. It has been accepted for inclusion in Pediatrics Faculty Publications by an authorized administrator of Health Sciences Research Commons. For more information, please contact hsrc@gwu.edu.

Authors

Kathleen Kieran, James R Anderson, Jeffrey S Dome, Peter F Ehrlich, Michael L Ritchey, Robert C Shamberger, Elizabeth J Perlman, Daniel M Green, and Andrew M Davidoff



Review Articles

Is adrenalectomy necessary during unilateral nephrectomy for Wilms Tumor? A report from the Children's Oncology Group^{☆,☆☆}

Kathleen Kieran^{a,*}, James R. Anderson^b, Jeffrey S. Dome^c, Peter F. Ehrlich^d, Michael L. Ritchey^e, Robert C. Shamberger^f, Elizabeth J. Perlman^g, Daniel M. Green^h, Andrew M. Davidoff^a

^aDepartment of Surgery, St. Jude Children's Research Hospital, Memphis, TN, USA

^bChildren's Oncology Group-Data Center (Omaha), Nebraska Medical Center, Omaha, NE, USA

^cDivision of Oncology, Children's National Medical Center, Washington, DC, USA

^dDepartment of Pediatric Surgery, C. S. Mott Children's Hospital, Ann Arbor, MI, USA

^eDivision of Urology, Phoenix Children's Hospital, Phoenix, AZ, USA

^fDepartment of Surgery, Children's Hospital Boston and Harvard Medical School, Boston, MA, USA

^gDepartment of Pathology, Northwestern University Feinberg School of Medicine and Robert H. Lurie Cancer Center, Chicago, IL, USA

^hDepartment of Epidemiology and Cancer Control, St. Jude Children's Research Hospital, Memphis, TN, USA

Received 30 November 2012; revised 26 April 2013; accepted 29 April 2013

Key words:

Adrenalectomy;
Wilms tumor;
Pediatric renal tumor

Abstract

Purpose: To determine whether performing adrenalectomy at the time of nephrectomy for unilateral Wilms tumor impacts clinical outcome.

Methods: We reviewed information on all patients enrolled on National Wilms Tumor Study-4 and -5. Data were abstracted on patient demographics, tumor characteristics, surgical and pathologic status of the adrenal gland, and patient outcomes. The primary endpoints were intraoperative spill and five-year event-free survival (EFS) in patients who did or did not undergo adrenalectomy.

Results: Of 3825 patients with complete evaluable data, the adrenal was left in situ in 2264 (57.9%) patients, and was removed completely in 1367 patients (36.7%) or partially in 194 patients (5.2%). Of the adrenal glands removed, 68 (4.4%) contained tumor. Adrenal involvement was more common in patients with stage 3 (9.8%) than stage 2 disease (1.9%; $p < 0.0001$). After controlling for stage and histopathology, five-year EFS was similar whether or not the adrenal gland was removed ($p = 0.48$), or involved with tumor ($p = 0.81$); however, intraoperative spill rates were higher in patients undergoing adrenalectomy (26.1% vs

[☆] Presented at the Surgical Section of the American Academy of Pediatrics meeting, Boston, MA, October, 2011.

^{☆☆} This project was supported by grants CA42326 (to the National Wilms Tumor Study), CA98543 (to the Children's Oncology Group), and CA021765 (to St. Jude Children's Research Hospital) from the National Institutes of Health, as well as the American Lebanese Syrian Associated Charities. We thank the many pathologists, surgeons, pediatricians, radiation oncologists, and other health professionals who managed the children enrolled in the National Wilms Tumor Studies.

* Corresponding author. University of Iowa, Department of Urology, 200 Hawkins Dr., 3 RCP, Iowa City, IA 52242-1089, USA. Tel.: +1 319 384 9448; fax: +1 319 356 3900.

E-mail address: kathleen-kieran@uiowa.edu (K. Kieran).

15.5%, $p < 0.0001$), likely due to larger tumor size or technical factors. No patient had clinical evidence of adrenal insufficiency or tumor recurrence in the adrenal gland during follow-up (median 9.9 years).

Conclusions: Sparing the adrenal gland during nephrectomy for unilateral Wilms tumor was not associated with a higher incidence of intraoperative spill and was associated with a similar oncologic outcome, on a per-stage basis, with cases where the adrenal was removed. Thus, adrenalectomy should not be considered mandatory during radical nephrectomy for Wilms tumor.

© 2013 Elsevier Inc. All rights reserved.

The National Wilms Tumor Study Group (NWTSG) conducted a series of multi-institutional clinical trials, beginning in 1969, which have identified prognostic factors and optimized treatment regimens for patients with Wilms tumor [1]. Based on this experience, the current standard of care for patients with localized Wilms tumor in North America is upfront unilateral nephrectomy with lymph node sampling. Histopathologic subtype and pathologic stage of the tumor determine the need for, and duration and intensity of, adjuvant chemotherapy and radiation therapy [2,3].

While it is generally accepted that the primary surgical objective in patients with localized Wilms tumor is complete resection of the neoplasm without spill, extensive resection of adjacent viscera to achieve a complete resection is discouraged because of the sensitivity of Wilms tumor to adjuvant therapy. However, although a classic radical nephrectomy includes resection of the ipsilateral adrenal gland [4], there are currently no specific recommendations regarding adrenalectomy in patients with clinically localized Wilms tumor; the management of the adrenal gland has typically been left to the discretion of the operating surgeon. There is also a dearth of literature on the incidence of adrenal involvement in patients with Wilms tumor; two published series report adrenal involvement in fewer than 2% of patients [5,6]. In addition, no studies have specifically addressed differential spill and survival rates based on whether or not the adrenal gland was removed as part of a radical nephrectomy in patients with unilateral Wilms tumor. Although patients with adrenal involvement can still be classified as stage 2 if all disease is resected with negative margins [7], (and therefore receive only two-drug chemotherapy following nephrectomy), the need to perform adrenalectomy when the adrenal appears to be uninvolved with tumor is unclear and may be driven more by the desire to avoid tumor rupture.

Conversely, adrenal insufficiency has very rarely been described following unilateral adrenal resection for either primary adrenal disease or as part of radical nephrectomy [8-10] and has never been observed in the NWTSG experience. Nevertheless, this condition can be life-threatening in its acute manifestation and, when chronic, mandates lifelong mineralocorticoid and glucocorticoid replacement, with the attendant side effects of these medications. Furthermore, metachronous contralateral tumors are seen in approximately 1% of patients with unilateral Wilms tumor [11], and patients in whom the ipsilateral adrenal gland was removed as a matter of course during resection of the primary

tumor may have fewer options for management of the recurrent disease without inducing adrenal insufficiency. Given the need to balance oncologic control and the potentially deleterious side effects of adrenalectomy, we undertook this study to formally assess the impact of adrenalectomy on clinical outcomes. The goal of this study was to determine the prognostic impact of adrenalectomy in patients treated on NWTSG-4 and -5; specifically, whether adrenalectomy was associated with variations in event-free survival (EFS) or intraoperative spill rates in patients with unilateral, localized Wilms tumor.

1. Methods

After obtaining Institutional Review Board approval, the records of 3913 patients were reviewed; all were enrolled in the NWTSG-4 and -5 studies and had undergone unilateral nephrectomy for non-metastatic Wilms tumor. Enrollment for NWTSG-4 and -5 was ongoing between August 1986 and May 2002. Since therapy for unilateral, nonmetastatic Wilms tumor was similar in NWTSG-4 and -5, with the primary difference being duration of therapy for favorable histology disease, the results from these two studies were combined for analysis. Patients who received pre-nephrectomy chemotherapy or who underwent partial nephrectomy for bilateral (or unilateral) disease, as well as those with evidence of metastatic disease were excluded. Patients with a diagnosis of clear cell sarcoma of the kidney, rhabdoid tumor of the kidney, or renal cell carcinoma were also excluded.

Data collected included patient demographics, tumor histopathology, surgical status of the adrenal gland (e.g. removed, preserved, or partially removed), the presence or absence of tumor in the adrenal gland, margin status, tumor weight, presence and extent of intraoperative spill, and pathologic stage. All histopathologic data were abstracted from the central pathology report except when slides of resected adrenal tissue were not sent for central review; in these few patients, the institutional assessment of adrenal involvement was recorded.

Event-free survival (EFS) was defined as the time from study entry until the first occurrence of disease progression, relapse after response, or death as a first event from any cause. Follow-up for patients not experiencing an event was censored at the time of last follow-up. Kaplan–Meier curves were calculated to estimate five-year EFS for various patient subsets.

Table 1 Surgical management of the adrenal gland, stratified by disease stage.

Adrenal Status	Stage		
	1	2	3
Left In Situ	1016 (72%)	736 (55%)	512 (47%)
Partially Removed	54 (4%)	76 (6%)	64 (6%)
Completely Removed	347 (24%)	515 (39%)	505 (47%)

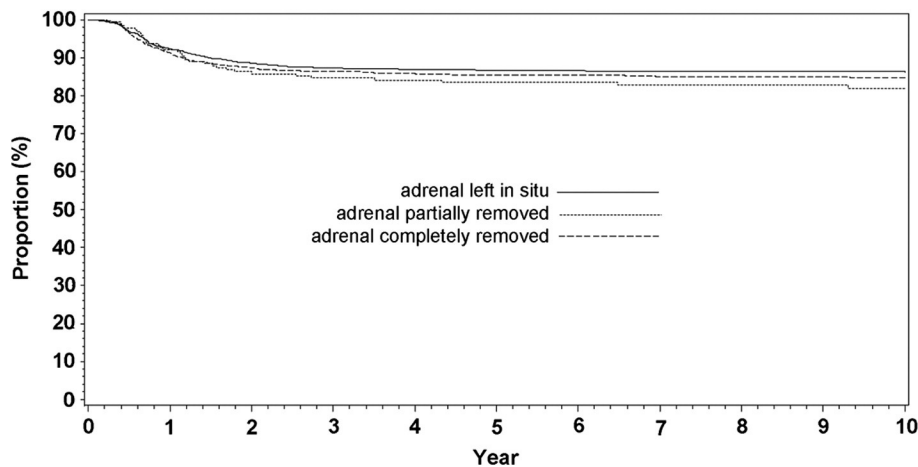
The EFS among patient subsets was compared using the log-rank test. Cumulative incidence rates of tumor bed recurrences were estimated treating all other failure types as competing risks. The independent contribution of various factors to the prediction of EFS was assessed using the Cox proportional hazards model. Differences were considered statistically significant if $p < 0.05$. Analyses were performed using commercially available statistical software (SAS, Cary, NC).

2. Results

The records of 3913 patients were reviewed. Eighty-eight (2.2%) cases were excluded from the analysis because details about either the surgical or pathologic status of the adrenal gland, or data on disease stage were unavailable. For the remaining 3825 patients, the adrenal gland was completely resected in 1367 (35.7%) patients and preserved in 2264 (59.2%) patients. In the remaining 194 (5.1%) patients, the adrenal gland was partially removed en bloc with the nephrectomy specimen, with the surgeon specifically noting the intent to preserve a portion of the gland. Adjuvant therapy based on tumor stage and histology was administered per the contemporary COG protocols, including flank radiation for positive surgical margins or tumor spill. Adrenal involvement per se did not alter therapy. Patients in whom the adrenal was involved but completely resected en bloc were considered stage II. Patients with involvement at the resection margin were considered stage III and received 3 drugs and flank RT.

In patients in whom the adrenal was at least partially removed, the histology of the primary tumor was favorable in 1446 (92.6%) cases, focal anaplasia in 20 (1.3%) cases, and diffuse anaplasia in 95 (6.1%) cases. In patients in whom the adrenal was preserved, the histology of the primary tumor was favorable in 2099 (92.7%) cases, focal anaplasia in 39 (1.7%) cases, and diffuse anaplasia in 126 (5.6%) cases. Thus, overall, tumor histopathology was similar in patients in whom the adrenal was removed and those in whom it was preserved ($p = 0.45$). Tumors in which the adrenal gland was partially (664 ± 423 g) or completely (671 ± 382 g) removed were larger than those in which the adrenal gland was left in situ (524 ± 378 g; $p < 0.0001$). Table 1 describes the surgical management of the adrenal gland, stratified by the pathologic stage of disease; adrenalectomy was more common in patients with higher stage disease ($p < 0.0001$).

Five-year EFS was similar in patients in whom the adrenal gland was partially (84%) or entirely (86%) removed compared with patients in whom the adrenal gland was left in situ (87%, $p = 0.23$; Fig. 1), even after adjusting for stage and histopathology ($p = 0.48$). The intraoperative spill rate was 26.1% (408/1561) in patients in whom the adrenal was removed compared with 15.5% (351/2264; $p < 0.0001$) in patients in whom the gland was preserved. Sixty-eight (4.4%) of the 1561 patients in whom the adrenal was evaluated had direct tumor extension or metastases into the adrenal gland or periadrenal fat. Of these 68 patients, 26 (38.2%) had gross involvement of the adrenal gland (23 by direct invasion and three with discrete metastatic disease), 35 (51.4%) had microscopic invasion only, and 7 (10.2%) had

**Fig. 1** Five-year EFS in all patients, stratified by surgical status of the adrenal gland ($p = 0.23$).

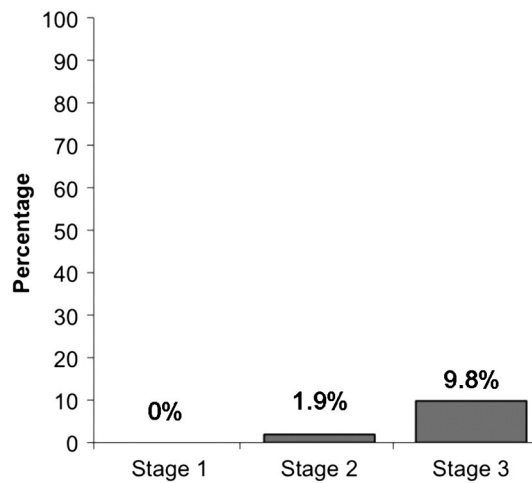


Fig. 2 Adrenal involvement with tumor, stratified by pathologic stage ($p < 0.0001$).

involvement of the periadrenal fat only. Adrenal involvement was similar whether the tumor was located in the left (4.5%) or right (3.8%) kidney ($p = 0.60$), but was more common in patients with higher stage disease ($p < 0.0001$; Fig. 2). After controlling for stage and histopathology, five-year EFS in patients with adrenal involvement was 82% compared to 85% for patients without adrenal gland involvement and 87% for patients in whom the adrenal was not evaluated ($p = 0.81$; Fig. 3).

Of 551 patients with recurrent disease, 96 (17.4%) had recurrence in the initial operative bed. Thirty-eight (39.6%) of these patients had adrenal tissue available for analysis, of whom only one (2.6%) had adrenal involvement at the time of initial surgery. Five-year cumulative recurrence rates in the operative bed were similar in patients in whom the adrenal was entirely (2.1%), partially (3.1%), or not (3.5%) removed ($p = 0.53$). No patient was recorded as having a recurrence within the adrenal gland itself. Patients with favorable histology had similar rates of adrenal involvement (4.1%)

compared with patients with focal (10%) or diffuse (7.4%) anaplasia ($p = 0.10$). Clinical evidence of acute or chronic adrenal insufficiency following adrenalectomy was not reported in any patient in our series; however, patients were not routinely tested for subclinical adrenal insufficiency.

3. Discussion

There are no specific, evidence-based recommendations in current COG protocols on how to manage the ipsilateral adrenal gland when performing a nephrectomy for unilateral Wilms tumor. Thus, the decision is left to the operating surgeon and is probably based on a variety of considerations including the desire to avoid tumor rupture and remove all disease while sparing uninvolved organs, including the adrenal gland. In this study, five-year event-free survival did not differ whether or not concurrent adrenalectomy was performed at the time of nephrectomy, suggesting that routine adrenalectomy does not confer a benefit for oncologic control when it is feasible to spare the adrenal gland. Whether or not adrenalectomy was performed, oncologic outcome remained similar even after controlling for disease histology and stage. Although the oncologic status of the adrenal glands left in situ cannot be known, our data suggest that even if some glands harbored microscopic tumor, there is no benefit to the surgical management of micrometastatic adrenal disease. Our findings are similar to those in a smaller Canadian series which found only four (6.9%) of 58 excised adrenal glands had tumor within the gland itself or within the periadrenal fat, and that tumor spillage rates were higher (though not significantly so) in patients undergoing adrenalectomy [6].

In renal cell carcinoma, risk factors for adrenal involvement can be identified preoperatively [12,13], and in patients without clinical or radiographic evidence of adrenal disease, routine adrenalectomy did not improve

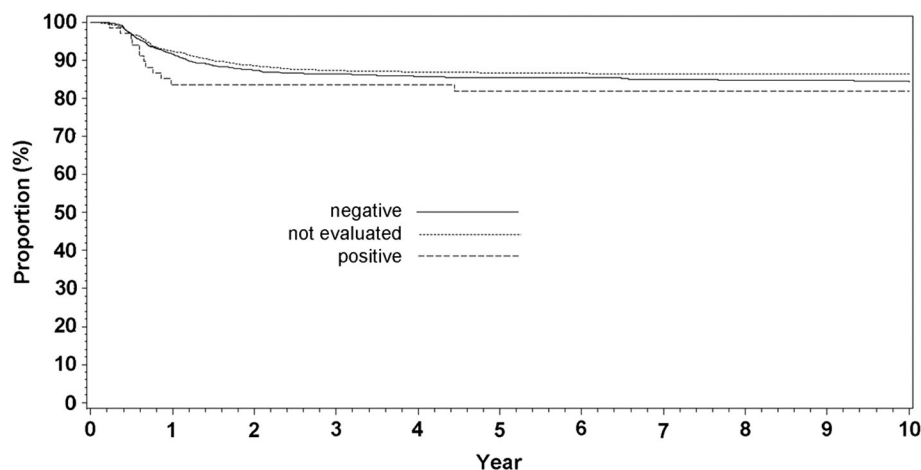


Fig. 3 Five-year EFS in all patients, stratified by pathologic status of the adrenal gland ($p = 0.81$).

oncologic outcome [13–16]. Since adrenal involvement is much less common and adjuvant therapy much more effective in Wilms tumor than renal cell carcinoma, this further underscores our finding that the risks of routine adrenalectomy in patients with Wilms tumor likely outweigh the potential benefits.

Intraoperative tumor spill rates were actually higher in patients in whom adrenalectomy was performed. While a full analysis of tumor spill and risk factors is not the focus of this paper, it is likely that characteristics of the tumor which would render tumor resection more technically challenging and might independently increase spill risk (e.g. size, proximity to other structures, friability) would influence the decision of the surgeon to resect or attempt to preserve the adrenal gland at the time of nephrectomy. This is supported by our finding that patients in whom adrenalectomy was performed tended to have larger tumors than those in whom the gland was left in situ. We do not believe that the technical performance of adrenalectomy contributed to the higher rate of tumor spill. Prior studies have suggested that tumor size (larger than 10 cm diameter) is the main factor that affects tumor spill. Tumor diameter and other tumor characteristics, such as location within the kidney, were not routinely recorded in all patients, making it difficult to control for these factors and more precisely define the independent impact of adrenalectomy on tumor spill [17].

Interestingly, we did not find that the five-year EFS was worse in patients in whom there was adrenal involvement with tumor, compared to those patients who had no adrenal involvement or those in whom the adrenal was not sampled. This suggests that the histopathologic status of the adrenal gland does not directly affect oncologic outcome; patients in whom the adrenal was removed may have had a more technically challenging surgery, with the need to perform a wide resection inclusive of the adrenal gland being a marker for complex tumor or patient characteristics which may independently increase the risk of spill. Since a large proportion of patients with adrenal involvement had microscopic disease, it is possible that some patients in whom the adrenal was left in situ also had microscopic metastatic disease which was effectively treated by chemotherapy, and thus, may not be clinically relevant.

The rate of adrenal involvement in our series was minimal (1.2%) in patients with completely resected (Stage 1 or 2) disease, compared with 10% in patients with Stage 3 disease; the similar clinical outcomes in these groups likely reflect the high sensitivity of Wilms tumor to chemotherapeutic agents and radiotherapy. Since only a small number of patients with focal and diffuse anaplasia had adrenal involvement, five-year EFS was not stratified by histopathologic subtype; again, however, differential survival rates with adrenal involvement in patients with diffuse anaplasia compared with those with favorable or focal anaplastic histology would likely support a role for both tumor histopathology and chemotherapy as mitigating factors in the prognosis of adrenal involvement.

However, the limited number of patients with anaplasia in our series precludes a formal analysis.

Previous reports from the National Wilms Tumor Study have found an important role for intraoperative decision making in the surgical management of Wilms tumor [18–20]. Thus, our finding that adrenalectomy rates rose in parallel with increasing clinical stage is not surprising, given that surgeons would likely seek to achieve a more extensive resection in patients in whom intraoperative findings suggested more extensive disease to avoid tumor rupture. However, our study design does not permit us to retrospectively assess a surgeon's rationale for removing the adrenal gland; in some cases, preservation may have been made technically challenging by the location and size of the primary tumor, whereas adrenal involvement may have been suspected in other patients based on visual or palpable findings evident only at the time of surgery. We are also unable to assess whether there was unequivocal radiographic evidence for or against adrenal involvement on preoperative imaging; the original cross-sectional imaging was not available for review, and only a small minority of radiology reports specifically addressed the intrarenal location of the tumor or the radiographic status of the adrenal gland. Unquantifiable intraoperative variables may also explain why the five-year EFS rate is higher in patients in whom the adrenal was not assessed compared to those in whom the adrenal was removed (regardless of the gland's oncologic status); it is possible that patients in whom the location and size of the primary tumor favored adrenal preservation fared better than those in whom the adrenal was resected, based on factors related to the primary tumor rather than the adrenal gland itself.

Currently, the decision to remove the adrenal or leave the gland in situ is made by the surgeon at the time of nephrectomy, and is likely based on the size and location of the primary tumor, ease of adrenalectomy, and suspicion for adrenal involvement, among other factors. Based on the low rate of adrenal involvement, and lack of apparent oncologic benefit to adrenalectomy concurrent with nephrectomy seen in our study, routine adrenalectomy does not appear to be mandatory.

References

- [1] Breslow N, Olshan A, Beckwith JB, et al. Epidemiology of Wilms tumor. *Med Pediatr Oncol* 1993;21:172-81.
- [2] Breslow N, Sharples K, Beckwith JB, et al. Prognostic factors in nonmetastatic, favorable histology Wilms' tumor. Results of the Third National Wilms' Tumor Study. *Cancer* 1991;68:2345-53.
- [3] Shamberger RC, Guthrie KA, Ritchey ML, et al. Surgery-related factors and local recurrence of Wilms tumor in National Wilms Tumor Study 4. *Ann Surg* 1999;229:292-7.
- [4] Robson C, Churchill BM, Anderson W. The results of radical nephrectomy for renal cell carcinoma. *J Urol* 1969;101:297-301.
- [5] Varan A, Büyükpamukçu N, Çağlar M, et al. Prognostic significance of metastatic site at diagnosis in Wilms' tumor: results from a single center. *J Pediatr Hematol Oncol* 2005;27:188-91.

- [6] Moore K, Leslie B, Salle JL, et al. Can we spare removing the adrenal gland at radical nephrectomy in children with Wilms tumor? *J Urol* 2010;184:1638-43.
- [7] Green DM. The treatment of stages I–IV favorable histology Wilms' tumor. *JCO* 2004;22:1366-72.
- [8] McNeill SA, Moussa SA, Bollina PR. Adrenal insufficiency complicating radical nephroureterectomy. *BJU Int* 1999;83:344-5.
- [9] Safir MH, Smith N, Hansen L, et al. Acute adrenal insufficiency following unilateral radical nephrectomy: a case report. *Geriatr Nephrol Urol* 1998;8:101-2.
- [10] Jones BV. Acute adrenal insufficiency after adrenalectomy. *BJU* 1949;2:1023-4.
- [11] Coppes MJ, Arnold M, Beckwith JB, et al. Factors affecting the risk of contralateral Wilms tumor development: a report from the National Wilms Tumor Study Group. *Cancer* 1999;85:1616-25.
- [12] Moudouni SM, En-Nia I, Patard JJ, et al. Real indications for adrenalectomy in renal cell carcinoma. *Scand J Urol Nephrol* 2002;36:273-7.
- [13] Tsui K-H, Shvarts, Barbaric Z, et al. Is adrenalectomy a necessary component of radical nephrectomy? UCLS experience with 511 radical nephrectomies. *J Urol* 2000;163:437-41.
- [14] Gill IS, McClennan BL, Kerbl K, et al. Adrenal involvement from renal cell carcinoma: predictive value of computerized tomography. *J Urol* 1994;152:1082-5.
- [15] Weight CJ, Kim SP, Lohse CM, et al. Routine adrenalectomy in patients with locally advanced renal cell cancer does not offer oncologic benefit and places a significant portion of patients at risk for an asynchronous metastasis in a solitary adrenal gland. *Eur Urol* [in press].
- [16] Kardar AH, Arafa M, Al Suhaibani H, et al. Feasibility of adrenalectomy with radical nephrectomy. *Urology* 1998;52:35-7.
- [17] Ritchey ML, Shamberger RC, Haase G, et al. Surgical complications after primary nephrectomy for Wilms' tumor: report from the National Wilms' Tumor Study Group. *J Am Coll Surg* 2001;192:63-8.
- [18] Leape LL, Breslow NE, Bishop HC. The surgical treatment of Wilms' tumor: results of the National Wilms' Tumor Study. *Ann Surg* 1978;187:351-6.
- [19] Othersen Jr HB, DeLorimer A, Hrabovsky E, et al. Surgical evaluation of lymph node metastases in Wilms' tumor. *J Pediatr Surg* 1990;25:330-1.
- [20] Kieran K, Dome JS, Ehrlich PF, et al. Lymph node sampling in Wilms tumor: what is "enough"? *J Ped Surg* 2012 [in press].