

4-28-2017

Cervical Ectropion May Be a Cause of Desquamative Inflammatory Vaginitis.

Leia Mitchell

Michelle King

Heather Brillhart
George Washington University

Andrew Goldstein

Follow this and additional works at: https://hsrc.himmelfarb.gwu.edu/smhs_obgyn_facpubs

 Part of the [Obstetrics and Gynecology Commons](#)

APA Citation

Mitchell, L., King, M., Brillhart, H., & Goldstein, A. (2017). Cervical Ectropion May Be a Cause of Desquamative Inflammatory Vaginitis.. *Sexual Medicine*, (). <http://dx.doi.org/10.1016/j.esxm.2017.03.001>

This Journal Article is brought to you for free and open access by the Obstetrics and Gynecology at Health Sciences Research Commons. It has been accepted for inclusion in Obstetrics and Gynecology Faculty Publications by an authorized administrator of Health Sciences Research Commons. For more information, please contact hsrc@gwu.edu.

SEXUAL MEDICINE

Cervical Ectropion May Be a Cause of Desquamative Inflammatory Vaginitis

Leia Mitchell, MSc,¹ Michelle King, MSc,^{1,2} Heather Brillhart, MD,³ and Andrew Goldstein, MD^{1,3}

ABSTRACT

Desquamative inflammatory vaginitis is a poorly understood chronic vaginitis with an unknown etiology. Symptoms of desquamative inflammatory vaginitis include copious yellowish discharge, vulvovaginal discomfort, and dyspareunia. Cervical ectropion, the presence of glandular columnar cells on the ectocervix, has not been reported as a cause of desquamative inflammatory vaginitis. Although cervical ectropion can be a normal clinical finding, it has been reported to cause leukorrhea, metrorrhagia, dyspareunia, and vulvovaginal irritation. Patients with cervical ectropion and desquamative inflammatory vaginitis are frequently misdiagnosed with candidiasis or bacterial vaginosis and repeatedly treated without resolution of symptoms. We report the case of a 34-year-old woman with a 4-year history of profuse yellowish discharge and dyspareunia. Upon presentation, her symptoms and laboratory results met the criteria for desquamative inflammatory vaginitis, but the standard treatments did not provide long-lasting relief. As a last resort, cryotherapy (cryosurgery) of her cervix was performed for treatment of her cervical ectropion, which provided complete resolution of her symptoms. **Mitchell L, King M, Brillhart H, Goldstein A. Cervical Ectropion May Be a Cause of Desquamative Inflammatory Vaginitis. Sex Med 2017;X:XX–XX.**

Copyright © 2017, The Authors. Published by Elsevier Inc. on behalf of the International Society for Sexual Medicine. This is an open access article under the CC BY-NC-ND license (<http://creativecommons.org/licenses/by-nc-nd/4.0/>).

Key Words: Desquamative Inflammatory Vaginitis; Cervical Ectropion; Cryotherapy; Cervical Ectopy; Cryosurgery; Cervicitis

INTRODUCTION

Desquamative inflammatory vaginitis (DIV) is a poorly understood chronic inflammatory vaginitis characterized by copious yellow discharge, vaginal irritation, and dyspareunia. Examination of the vaginal discharge shows a pH of at least 4.5, increased polymorphonuclear leukocytes (a ratio of polymorphonuclear leukocytes to epithelial cells > 1:1), and many parabasal cells.^{1,2} It has been suggested that DIV could be a severe form of aerobic vaginitis.³ Vaginal cultures can grow group B *Streptococcus* species and/or *Escherichia coli* but are frequently negative for infectious pathogens.³ It has been reported that up to 27% of patients with DIV have multiple small erythematous macules on their ectocervix.² This finding has been called

“colpitis macularis” or “papular colpitis” and is similar to the ectocervical findings of a *Trichomonas vaginalis* infection.^{2,4} The diagnosis of DIV is one of exclusion, and other causes of vaginal inflammation must be ruled out, including *T vaginalis*, group A *Streptococcus* species, erosive lichen planus, atrophic vaginitis, seminal plasma hypersensitivity, and irritant vaginitis. Although the etiology of DIV is unknown, it has been postulated that estrogen deficiency, toxins from *Staphylococcus aureus*, or an immunologic process might be the cause.¹

Cervical ectropion is the presence of columnar cells on the ectocervix, which is normally composed of a squamous epithelium. Potential causes of ectropion include adolescent age, pregnancy, and hormonal contraceptives.⁵ Some clinicians believe ectropion could be a normal asymptomatic variant, whereas others believe it to be correlated with chronic cervicitis.⁵ The presence of the metaplastic columnar epithelium can manifest a myriad of symptoms including increased vaginal discharge, leukorrhea, postcoital bleeding, pelvic pain, recurrent cervicitis, and dyspareunia.^{5–8} Although the symptoms of ectropion overlap with DIV, it has not been reported as a cause of DIV.

CASE REPORT

A 34-year-old G2P2002 woman presented to a center specializing in vulvovaginal disorders for evaluation of a 4-year

Received November 30, 2016. Accepted March 16, 2017.

¹The Centers for Vulvovaginal Disorders, Washington, DC, and New York, NY, USA;

²Nova Southeastern University College of Osteopathic Medicine, Fort Lauderdale, FL, USA;

³George Washington University School of Medicine and Health Sciences, Washington, DC, USA

Copyright © 2017, The Authors. Published by Elsevier Inc. on behalf of the International Society for Sexual Medicine. This is an open access article under the CC BY-NC-ND license (<http://creativecommons.org/licenses/by-nc-nd/4.0/>).

<http://dx.doi.org/10.1016/j.esxm.2017.03.001>

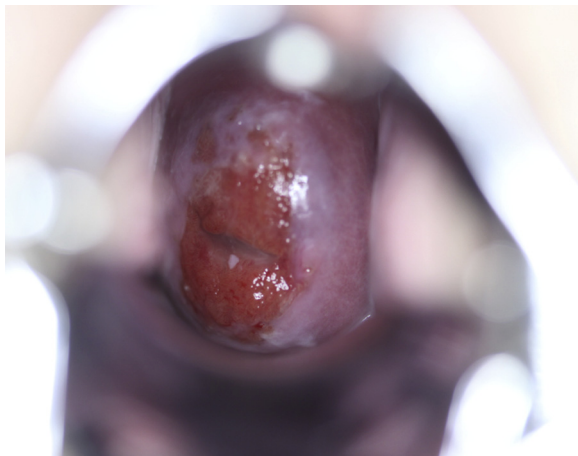


Figure 1. Image of patient's cervix with ectopy before cryotherapy.

history of persistent vulvovaginal pruritus, irritation, copious yellowish discharge, and introital dyspareunia. Before her presentation at the vulvovaginal clinic, she had been seen by multiple health care providers and had been treated with many courses of antimycotics and antibiotics including oral fluconazole, topical terconazole, topical and oral metronidazole, topical clindamycin, and topical nystatin. Unfortunately, she had no long-term improvement of her symptoms with these treatments.

On physical examination she was noted to have erythema and tenderness of her vulvar vestibule. Examination of her vaginal vault showed copious purulent vaginal discharge with erythema and tenderness of the vaginal mucosa, without lesions, ulcerations, erosions, or synechiae. The cervix was non-friable, without evidence of cervicitis, but cervical ectropion was noted (Figure 1). The pH of the vaginal discharge was 5.0 and light microscopy showed many leukocytes and parabasal cells. The vaginal culture obtained at presentation was negative for pathogens *T vaginalis*, *Chlamydia trachomatis*, *Neisseria gonorrhoeae*, and *Mycoplasma genitalium*.

The patient was initially given the diagnosis of DIV, and because of her failed treatment with clindamycin, she was treated with intravaginal hydrocortisone as described by Sobel et al.⁹ Although she initially had complete resolution of her symptoms with this treatment, every time she stopped the intravaginal hydrocortisone, her symptoms recurred. Because the patient desired definitive treatment for her symptoms, she was offered cryotherapy (cryosurgery) as a treatment for her ectropion and as a possible treatment for her DIV.

Using a Graves speculum, the cervix was visualized and an appropriately sized cryo-tip and nitrous oxide were used to freeze the ectocervix for 90 seconds (LLCO₂ System, Wallach Surgical Devices, Trumbull, CT, USA).⁶ Spontaneous thawing occurred within 60 seconds of the cessation of freezing. An additional freeze-thaw cycle was performed. The patient tolerated the procedure and had an uneventful postprocedure recovery.

The patient returned 9 weeks after cryosurgery and reported significant improvement in her vulvovaginal irritation and

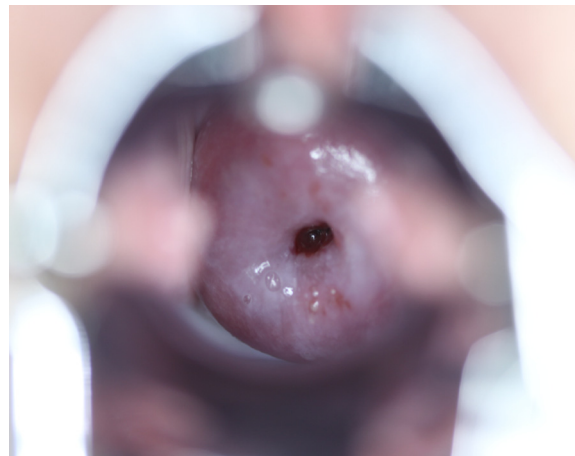


Figure 2. Image of patient's cervix 9 weeks after cryotherapy. The cervical ectropion has resolved.

vaginal discharge since the procedure. She reported several weeks of clear, watery discharge after the procedure, but she denied any symptoms at the time of follow-up. At physical examination, the cervix was normal in appearance, with complete resolution of the ectropion (Figure 2). The vaginal mucosa was no longer erythematous or tender and there was minimal thin white discharge. Wet mount examination displayed very few leukocytes and no parabasal cells. Additional follow-up appointments, up to 34 months after her cryotherapy, confirmed persistent resolution of her ectropion (Figure 3) and DIV symptoms.

DISCUSSION

DIV is a poorly understood chronic inflammatory vaginitis that accounts for 8% of patients with chronic vaginitis and is most common in perimenopausal women, although it is diagnosed in a wide age range.^{1,10} Therefore, our patient is somewhat unusual because she had DIV at 34 years of age. On average, women typically have DIV symptoms for 15 to 31 months before diagnosis.^{2,9} Although there have been no randomized

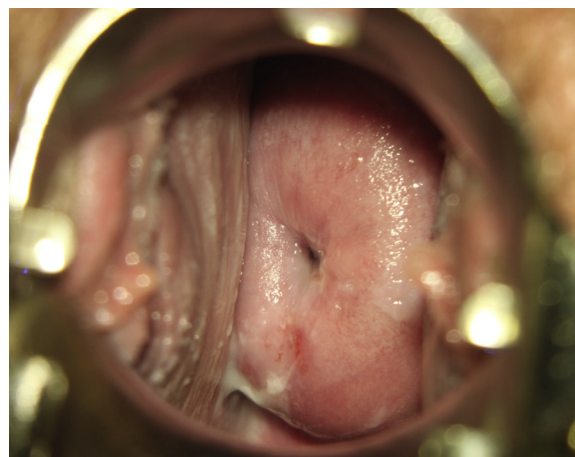


Figure 3. Image of patient's cervix 34 months after cryotherapy.

controlled trials for the treatment of DIV, Sobel et al⁹ reported on a case series of 98 women who had high rates of improvement in symptoms with one of three treatments: vaginal clindamycin 2% cream, vaginal hydrocortisone 10% cream, or cortisone acetate 25 mg vaginal suppositories.⁹ They reported that 86% of women initially had improvement in symptoms with these treatments, but that 33% of patients had relapse within 6 weeks of treatment cessation and more than 58% of women required long-term maintenance therapy to remain asymptomatic. Sobel et al concluded that DIV is a chronic condition that requires long-term maintenance therapy in most patients.

The treatment goal for symptomatic ectropion is to destroy the glandular columnar epithelium, thereby inducing squamous metaplasia, leading to the resolution of vulvovaginal pruritus, irritation, yellowish discharge, and dyspareunia. Reported treatment modalities include laser ablation, microwave ablation, focused ultrasound, platelet-rich plasma injections, herbal therapies, and cryosurgery.^{6,7,11–13} Most studies have reported very high cure rates, such as a case series of 50 patients by Mohanty et al⁷ who reported a cure rate of 98% in patients who were treated with cryotherapy.

In conclusion, although it is common to find erythematous macules on the ectocervix of patients with DIV, the finding of concurrent cervical ectropion and DIV has not been reported. Our case illustrates the possibility that some patients with DIV can have an associated, although not necessarily causative, cervical ectropion. Therefore, given the minimal risks associated with cryotherapy, clinicians should consider this treatment in patients with concurrent DIV and ectropion in whom standard treatments for DIV have failed.

Corresponding Author: Leia Mitchell, The Centers for Vulvovaginal Disorders, 3 Washington Circle NW 205, Washington, DC 200075, USA; E-mail: leiamitchell11@gmail.com

Conflicts of Interest: The authors report no conflict of interest.

Funding: None.

STATEMENT OF AUTHORSHIP

Category 1

(a) Conception and Design

Leia Mitchell; Michelle King; Heather Brillhart; Andrew Goldstein

(b) Acquisition of Data

Leia Mitchell; Michelle King; Andrew Goldstein

(c) Analysis and Interpretation of Data

Leia Mitchell; Michelle King; Heather Brillhart; Andrew Goldstein

Category 2

(a) Drafting the Article

Leia Mitchell; Michelle King; Heather Brillhart; Andrew Goldstein

(b) Revising It for Intellectual Content

Leia Mitchell; Michelle King; Andrew Goldstein

Category 3

(a) Final Approval of the Completed Article

Leia Mitchell; Michelle King; Heather Brillhart; Andrew Goldstein

REFERENCES

1. Reichman O, Sobel J. Desquamative inflammatory vaginitis. *Best Pract Res Clin Obstet Gynaecol* 2014;28:1042-1050.
2. Sobel JD. Desquamative inflammatory vaginitis: a new subgroup of purulent vaginitis responsive to topical 2% clindamycin therapy. *Am J Obstet Gynecol* 1994;171:1215-1220.
3. Donders GG, Vereecken A, Bosmans E, et al. Definition of a type of abnormal vaginal flora that is distinct from bacterial vaginosis: aerobic vaginitis. *BJOG* 2002;109:34-43.
4. Van der Meijden WI, Ewing PC. Papular colpit: a distinct clinical entity? Symptoms, signs, histopathological diagnosis, and treatment in a series of patients seen at the Rotterdam vulvar clinic. *J Low Genit Tract Dis* 2011;15:60-65.
5. Hua X, Zeng T, Zhang R, et al. Using platelet-rich plasma for the treatment of symptomatic cervical ectopy. *Int J Gynaecol Obstet* 2012;119:26-29.
6. Cekmez Y, Sanlikan F, Gocmen A, et al. Is cryotherapy friend or foe for symptomatic cervical ectopy? *Med Princ Pract* 2016; 25:8-11.
7. Mohanty KC, Rand RJ, Berry B. Cryotherapy in the management of cervical ectopy. *Genitourin Med* 1985;61:335-337.
8. Jacobson DL, Peralta L, Graham N, et al. Histologic development of cervical ectopy: relationship to reproductive hormones. *Sex Transm Dis* 2000;27:252-258.
9. Sobel JD, Reichman O, Misra D, et al. Prognosis and treatment of desquamative inflammatory vaginitis. *Obstet Gynecol* 2011; 117:850-855.
10. Nyirjesy P, Peyton C, Weitz MV, et al. Causes of chronic vaginitis: analysis of a prospective database of affected women. *Obstet Gynecol* 2006;108:1185-1191.
11. Yang K, Li J, Liu Y, et al. Microwave therapy for cervical ectropion. *Cochrane Database Syst Rev* 2007;4:CD006227.
12. Chen J, Zhou D, Liu Y, et al. A comparison between ultrasound therapy and laser therapy for symptomatic cervical ectopy. *Ultrasound Med Biol* 2008;34:1770-1774.
13. Zhongxing S, Guilan L, Guangqin Z, et al. Therapeutic effects of traditional Chinese medicine in patients with symptomatic cervical ectopy. *Complement Ther Med* 2015;23:816-820.