

Himmelfarb Health Sciences Library, The George Washington University

Health Sciences Research Commons

GW Ophthalmology On-Call

Ophthalmology

9-2023

GW Ophthalmology On-Call: September 2023

Alexa Shahine

Andeulazia Murdock

Amandeep Ahluwalia

Abdulla Ahmed

Follow this and additional works at: https://hsrc.himmelfarb.gwu.edu/smhs_gw_ophthalm_on_call



OPHTHALMOLOGY
ON CALL

September 2023

*George Washington University
Department of Ophthalmology*

Table of Contents

Introduction.....	Page 3
Pattern Dystrophy.....	Page 4
Tuberous Sclerosis.....	Page 10
Acknowledgements.....	Page 14

Introduction

GW Ophthalmology On Call is a monthly case report publication presented by medical students and residents at the GW Department of Ophthalmology. The purpose of this publication series is to highlight educational content seen at the GW Department of Ophthalmology. This content is for teaching purposes only and should not be used to guide treatment. All case presentations have been written in accordance with HIPAA guidelines. Case details have been modified for patient privacy purposes.

Pattern Dystrophy

Alexa Shahine, Andeulazia Murdock, Masumi Asahi DO, Marena Patronas MD

Chief Complaint

New spot in left eye

History of Present Illness

A 42 year-old male presented for urgent evaluation after noticing a large gray spot (OS) near his central vision while watching TV the night before. He reports being stable since onset, without flashes/floaters, photophobia, recent trauma, headaches, or other ocular symptoms.

Ocular History

High myopia OU
Bilateral pattern dystrophy
Ocular migraines
Intermediate stage nonexudative AMD OU

Past Medical History

Testicular cancer s/p chemotherapy

Medications

PreserVision AREDs capsule once daily

Allergies

None

Family History

None

Social History

None

Review of Systems

None

Ocular Exam

Physical Exam		
	OD	OS
Visual Acuity	20/25-1	20/25-1
Intraocular Pressure (mmHg)	14	13
Pupils	Round and reactive	Round and reactive
Extraocular Motility	EOMI	EOMI

Slit Lamp Exam		
	OD	OS
External	Normal, no lesions	Normal, no lesions
Lids and Lashes	Normal, no lesions	Normal, no lesions
Conjunctiva/Sclera	White and quiet	White and quiet
Cornea	Clear	Clear
Anterior chamber	Moderate and quiet	Moderate and quiet
Iris	Round and reactive	Round and reactive
Lens	Clear	Clear

Dilated Fundus Exam		
	OD	OS
Cup to Disc	0.3	0.3
Optic Nerve	Normal	Normal
Vessels	Normal	Normal
Macula	Pigmentary mottling	Pigmentary mottling, vertical linear parafoveal hemorrhage without PVD
Periphery	Normal	Normal
Vitreous	Clear	Clear

Imaging

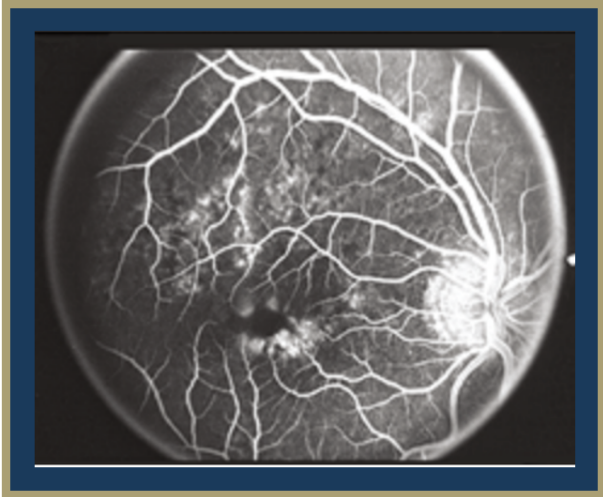


Figure 1: Fluorescein angiogram showing a large, hypofluorescent, butterfly-shaped macular lesion.

Adapted from: Zhang K, Garibaldi DC, Li Y, Green WR, Zack DJ. Butterfly-Shaped Pattern Dystrophy: A Genetic, Clinical, and Histopathological Report. *Arch Ophthalmol.* 2002;120(4):485–490. doi:10.1001/archophth.120.4.485

OCT mac

OD: normal foveal contour, dry, +drusen - stable

OS: mac PEDs, drusen, normal foveal contour, dry - stable

Differential Diagnosis

- 1) Pattern dystrophy
- 2) Age related macular degeneration
- 3) Stargadt disease
- 4) Retinal detachment

Clinical Course

Upon finding acute hemorrhage on a fundus exam with fluorescein angiography (FA), the patient was referred to the National Eye Institute for further evaluation. He was instructed to return to our ophthalmology clinic in 4 weeks for follow-up fundus imaging and optical coherence tomography (OCT).

At the 4 week follow up appointment, overall symptoms improved with the resolution of the acute hemorrhage. OCT was stable, unchanged, and without fluid on exam. He was started on daily Amsler grid monitoring and advised to call our clinic should he notice any worsening symptoms. Additionally, parental genetic testing was ordered with follow up with a genetic counselor. He continues to follow up on a regular basis for monitoring of AMD OU and macular pattern dystrophy OU.

Discussion

Macular pattern dystrophy refers to a set of retinal disorders involving bilateral symmetric vision loss due to lipofuscin buildup in the retinal pigment epithelium (RPE). Pattern dystrophy is associated with an autosomal dominant inheritance pattern and great phenotypic variability. Missense and nonsense mutations in the retinal degeneration slow (RDS) and peripherin gene on chromosome 6p21.1 are thought to be responsible for pattern dystrophy. Mutation of this gene causes dysfunction in the peripherin-2 protein (PRPH2) responsible for development and stabilization of outer disc segments in photoreceptors.¹ This can result in photoreceptor degeneration and lipofuscin deposition in the RPE. One study found that 85.7% of patients with maternally inherited diabetes and deafness (MIDD) were found to have macular pattern dystrophy on a fundoscopic exam.²

Pattern dystrophies are often an incidental finding on routine eye exam in asymptomatic patients, but some patients present with metamorphopsia (distorted vision) and/or decrease in vision. Symptoms typically begin in a patient's 30s to 40s and, over the course of the disease, patients will experience slowly progressive central vision loss.³

A distinct pattern of pigment deposition seen on fundoscopic exam will afford a clinical diagnosis of pattern dystrophy.³ Fluorescein angiography (FA), fundus autofluorescence (FAF), electrooculogram (EOG), and electroretinogram (ERG) can be used to identify the distinct pattern and stage of progression. FA will show an absence of dark choroid manifestation⁴ and FAF will show either increased or decreased hyperautofluorescence, depending on the extent of lipofuscin deposition.^{3,4,5} EOG and ERG are expected to be normal or show minimal changes. These results are helpful to differentiate pattern dystrophy from age-related macular degeneration, which would present with similar fundoscopic exam findings but abnormal EOG and ERG results. Manifestations of this pattern dystrophy are phenotypically diverse, so genetic testing for mutations in the PRPH2 gene is recommended as an adjunct to the aforementioned diagnostic measures, as seen in the management of this case .³

Visual prognosis is usually good for patients with pattern dystrophy; however, vision loss and secondary complications, such as choroidal neovascularization, can present based on the location of the pigment accumulation. After the onset of symptoms, patients may notice gradual changes to central vision as the disease progression is typically slow. Although there are currently no treatments for macular pattern dystrophy, current research is investigating genetic targets for future therapies. Often pattern dystrophy is misdiagnosed as AMD due to their similar presentation and patients receive unnecessary vitamins, anti-VEGF injections, and photodynamic therapy. To avoid this, a thorough workup, including genetic testing, is recommended to rule out AMD.

References

1. Zhang K, Garibaldi DC, Li Y, Green WR, Zack DJ. Butterfly-Shaped Pattern Dystrophy: A Genetic, Clinical, and Histopathological Report. *Arch Ophthalmol*. 2002;120(4):485–490. doi:10.1001/archophth.120.4.485
2. Massin, P., Virally-Monod, M., Vialettes, B., Paques, M., Gin, H., Porokhov, B., Caillat-Zucman, S., Froguel, P., Paquis-Fluckinger, V., Gaudric, A., & Guillausseau, P. J. (1999). Prevalence of macular pattern dystrophy in maternally inherited diabetes and deafness. GEDIAM Group. *Ophthalmology*, 106(9), 1821–1827. [https://doi.org/10.1016/s0161-6420\(99\)90356-1](https://doi.org/10.1016/s0161-6420(99)90356-1)
3. Ahmed, H., Sierpina, D. I., & Khazaeni, L. (2023). Retinal Pattern Dystrophy. In *StatPearls*. StatPearls Publishing.
4. Hanif, A. , Yan, J. & Jain, N. (2019). Pattern Dystrophy: An Imprecise Diagnosis in the Age of Precision Medicine. *International Ophthalmology Clinics*, 59 (1), 173-194. doi: 10.1097/IIO.0000000000000262.
5. Rahman, N., Georgiou, M., Khan, K. N., & Michaelides, M. (2020). Macular dystrophies: clinical and imaging features, molecular genetics and therapeutic options. *The British journal of ophthalmology*, 104(4), 451–460. <https://doi.org/10.1136/bjophthalmol-2019-315086>

Tuberous Sclerosis

Amandeep Ahluwalia, Abdulla Ahmed, Will Foos MD

Chief Complaint

Seizures and subsequent tuberous sclerosis diagnosis

History of Present Illness

A 4-month-old male was brought to the Children's National Hospital Emergency Department by his mother, seeking urgent medical attention due to recurrent seizures. These seizures were characterized by episodes of tense body shaking and eye shifting, each persisting for approximately 30 seconds. The patient had no prior known medical history, was afebrile, and had no recent history of illness. Following a thorough evaluation, the patient received a definitive diagnosis of tuberous sclerosis. As a result of this diagnosis, the patient was subsequently referred to the Ophthalmology department for ocular assessment.

Ocular History

None

Pertinent Past Medical History

Seizures

Medications

Corticotropin
Famotidine
Lorazepam
Fosphenytoin

Allergies

No known allergies

Family History

Mother - HER2+ breast cancer, Fe deficiency anemia
Father - HTN, hypercholesterolemia, T2DM
Paternal grandmother - breast cancer, seizures as a child (not reported to be infantile spasms), sarcoidosis

Social History

Conceived via IVF - maternal egg freezing prior to chemotherapy.

Review of Systems

All other systems intact

Ocular Exam

Physical Exam		
	OD	OS
Visual Acuity	Central, steady & maintained	Central, steady & maintained
Intraocular Pressure (via palpation)	Normal	Normal
Pupils	Round and reactive	Round and reactive
Extraocular Motility	EOMI	EOMI

Slit Lamp Exam		
	OD	OS
External	Small angiofibroma on the right lateral nasal bridge	Normal
Lids and Lashes	Normal	Normal
Conjunctiva/Sclera	White and quiet, inferior palpebral concretions	White and quiet, inferior palpebral concretions
Cornea	Clear	Clear
Anterior chamber	Deep and quiet	Deep and quiet
Iris	Round and reactive	Round and reactive
Lens	Clear	Clear

Imaging

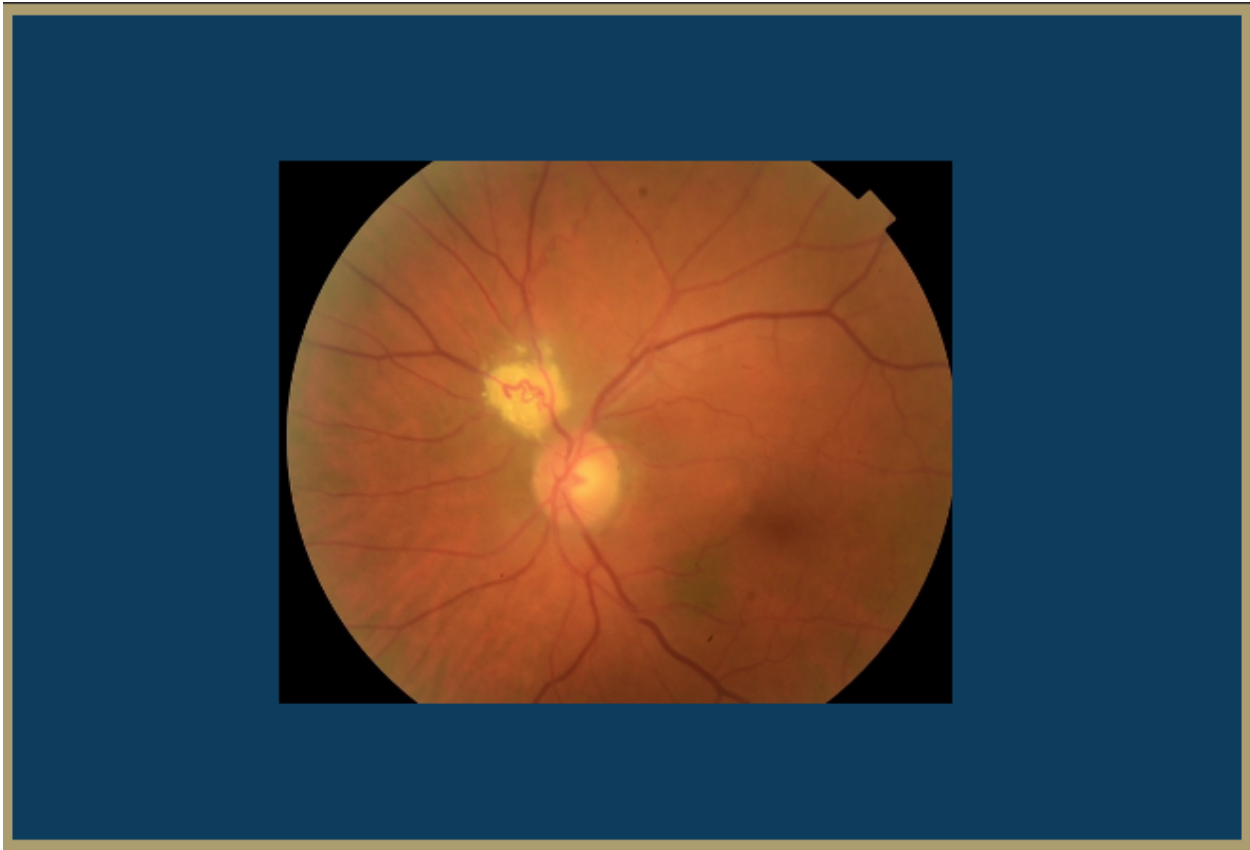


Figure 1: Fundus photo revealing a retinal astrocytoma.

Adapted from: Couceiro, R & Marques Neves, C. Retinal astrocytoma. *Retina Image Bank* (2015).
<https://imagebank.asrs.org/file/24871/retinal-astrocytoma>

Differential Diagnosis

Tuberous Sclerosis

Infantile Spasms

Glaucoma

Clinical Course

A 4-month old ex full-term male presented to the ED with seizure-like activity per mother. Seizure work-up revealed several tubers in the brain. Ophthalmology was consulted to evaluate for retinal astrocytomas and ophthalmic exam prior to considering initiating vigabatrin therapy. Exam revealed a small atrophic lesion in the left eye with no astrocytomas or hamartomas and the patient was cleared to begin vigabatrin therapy for seizure control. He follows with ophthalmology every 6-9 months for repeat exams.

Discussion

Tuberous sclerosis complex (TSC) is a genetic multi-system syndrome characterized by the development of benign tumors affecting the brain, skin, retina, kidneys and viscera leading to significant morbidity and mortality¹. This genetic disorder has no predilection for sex or ethnic group, and the estimated prevalence ranges from one in 6,000 to one in 12,000; approximately two-thirds of these cases are sporadic, while the remaining one-third are inherited in an autosomal dominant fashion². Classically, patients with TSC will present with any combination of the following: seizures, hypomelanotic macules, facial angiofibroma, shagreen patch, retinal hamartomas, renal angiomyolipoma, giant cell astrocytoma or cardiac rhabdomyoma. The presentation of TSC, however, is variable, and some manifestations are more common than others. For example, TSC-associated neuropsychiatric disorders are reported in 90% of children and adults and skin involvement occurs in nearly all individuals, while ophthalmologic features including retinal hamartomas are reported in 30%-50% of cases and achromatic patches in 39%³.

During the physical exam, a detailed dermatological exam should be performed, looking for hypomelanotic macules, angiofibromas, and shagreen patches. An oral and ophthalmologic exam should also be performed looking for intraoral fibromas and retinal hamartomas or retinal achromic patches, respectively. In our patient, the dermatological exam revealed a small angiofibroma on the right lateral nasal bridge. The ophthalmology exam yielded a small atrophic lesion in the left eye and no astrocytomas or hamartomas. These are the typical findings in a patient with Tuberous Sclerosis.

While benign, hamartomas can cause seizures, obstructions, arrhythmias, and mass effect which necessitates a thorough evaluation. Patients suspected of having TSC should be assessed for arrhythmias, which may be detectable by auscultation or palpation of pulse. A cranial MRI looking for subependymal nodules, subependymal giant cell astrocytomas, or cortical/subcortical tubers are appropriate if neurological manifestations appear to be dominant on presentation. Diagnosis can be made based on specific genetic criteria (pathogenic variant in either TSC1 or TSC2), or clinical diagnostic criteria (requires two major features and two or more minor features). For our patient, EEG confirmed infantile spasms and MRI revealed multiple cortical/subcortical tubers, white matter radial glial bands, and subependymal nodules, which are all characteristic of TSC. Interestingly, a genetic consult found that the patient's mother as well as his paternal grandmother had breast cancer, a disease that has association with TSC⁴. Furthermore, the patient's paternal grandmother had seizures as a child which bears resemblance to our patient's initial presentation.

Management of TSC depends on the specific disease manifestations present, however the mTORi's such as everolimus and sirolimus are frequently used as therapy for specific tumors arising in TSC as they are potent inhibitors of cell proliferation. Vigabatrin is first-line therapy for infantile spasms, while ACTH or prednisolone can also be added. Vigabatrin requires an ophthalmologic evaluation prior to initiation as it can cause retinal toxicity. The prognosis of TSC is highly variable due to the heterogeneity of disease presentation and number of organ

systems it can affect. Overall, CNS tumors and renal disease may lead to early death in some patients with TSC.

References

1. Caban C, Khan N, Hasbani DM, Crino PB. Genetics of tuberous sclerosis complex: implications for clinical practice. *Appl Clin Genet*. 2017;10:1–8. doi:10.2147/TACG.S90262
2. Cruess, Alan F., Sharma, Sanjay, Ryan's Retina, 132, Pages 2577-2584 © 2023, Elsevier Inc. All rights reserved.
3. Touraine, R., Hauet, Q., Harzallah, I., & Baruteau, A. E. (2022). Tuberous Sclerosis Complex: Genetic counselling and perinatal follow-up. *Archives de pediatrie : organe officiel de la Societe francaise de pediatrie*, 29(5S), 5S3–5S7. [https://doi.org/10.1016/S0929-693X\(22\)00283-4](https://doi.org/10.1016/S0929-693X(22)00283-4)
4. Mehta, M. S., Vazquez, A., Kulkarni, D. A., Kerrigan, J. E., Atwal, G., Metsugi, S., Toppmeyer, D. L., Levine, A. J., & Hirshfield, K. M. (2011). Polymorphic variants in TSC1 and TSC2 and their association with breast cancer phenotypes. *Breast cancer research and treatment*, 125(3), 861–868. <https://doi.org/10.1007/s10549-010-1062-1>

Acknowledgments

Case Report Authors

Pattern Dystrophy

Alexa Shahine, MS2

Andeulazia Murdock, MS2

Tuberous Sclerosis

Amandeep Ahluwalia, MS2

Abdulla Ahmed, MS2

Medical Student Editors

Yusuf Bade, BA MS2

Shaleen Arora, BS MS3

Resident Editors

Masumi Asahi, DO

Braedon Murdock, MD

William Foos, MD

Attending Reviewers

David Belyea, MD MBA

Marena Patronas, MD

Editors in Chief

Jason Dossantos, BS MS4

Julie Thomasian, MD