

Neuroimaging of Unusual Glioblastoma Using Diffusion Tensor Imaging

Akshita Mehta MSII¹, Lucien M. Levy MD PhD², M. Isabel Almira-Suarez MD³, Raymond Tu MD MS²
 GW School of Medicine and Health Science¹, GWU Medical Center, Department of Radiology², GWU
 Medical Center, Department of Pathology, Division of Neuropathology³

THE GEORGE
 WASHINGTON
 UNIVERSITY
 WASHINGTON, DC

Objectives

- Gliosarcoma is a particularly uncommon type of glioblastoma containing distinct gliomatous and sarcomatous constituents, with a substantial proportion of malignant mesenchymal cells.
- Accurate neuroimaging diagnosis is essential, and DTI and spectroscopy can be useful to differentiate from inflammatory disease.
- Gliosarcomas, a variant of glioblastoma, occurs in the same locations, particularly the central white matter or corpus callosum. They appear very similar on imaging with characteristic features including supratentorial and peripheral locations, abutment of a dural surface, uneven thick walled enhancement, and intratumoral strip enhancement.
- We report the MR imaging findings in an adult patient suggesting a gliosarcoma variant of a glioblastoma.

Methods

- We report a 38 year-old Caucasian male with a right occipital parietal lobe glioblastoma multiforme, who presented with new onset tonic-clonic seizures lasting approximately five minutes. Associated postictal confusion and incontinence were seen.
- The patient had conventional brain MRI scans including diffusion tensor imaging (Fig 3). MRI data was processed to obtain fractional anisotropy maps (Fig 4). MR images were examined for extent and location of tumor as well as invasion, destruction or displacement of brain parenchyma and white matter tracts. Non-contrast CT did not reveal any abnormality.

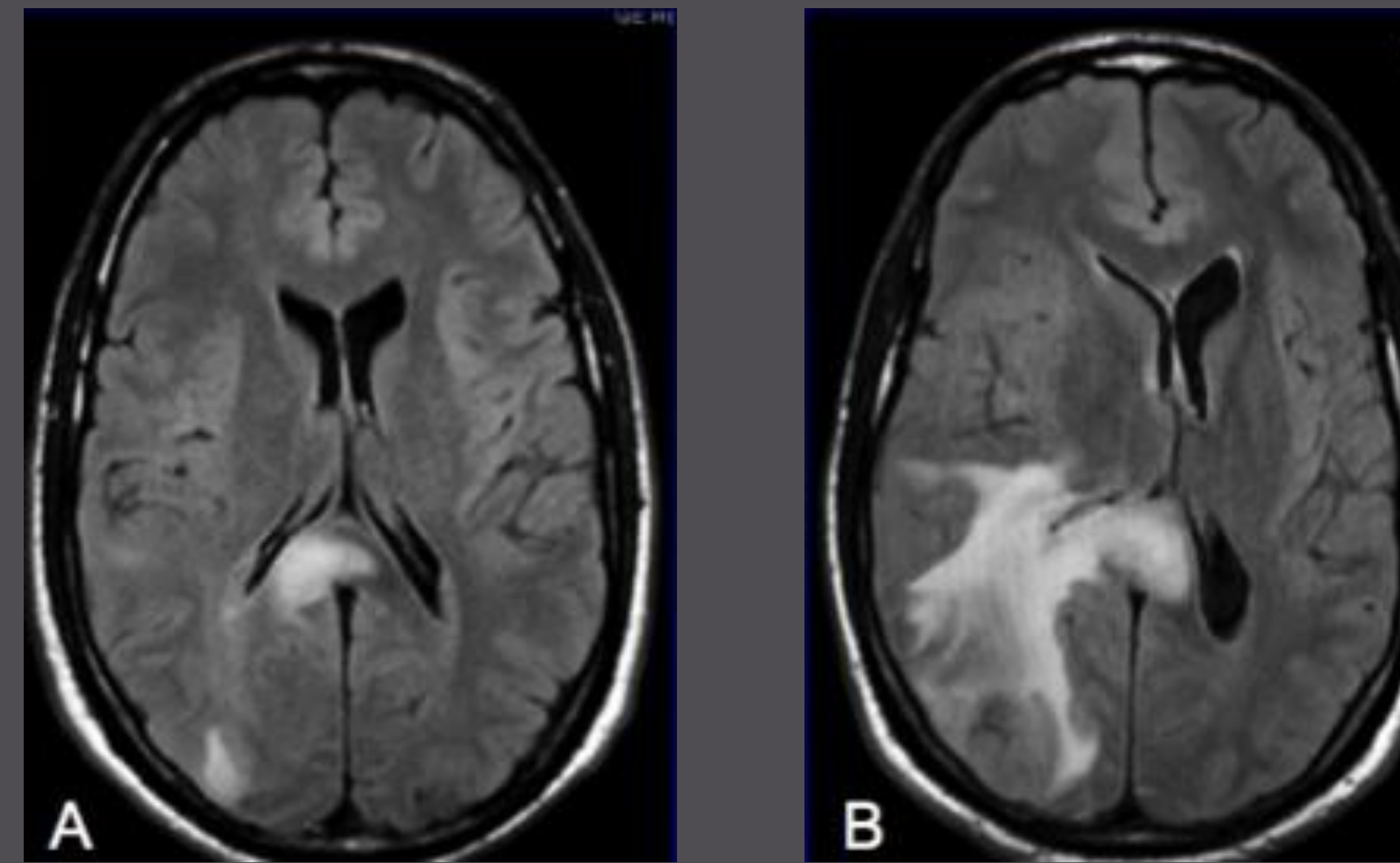


Figure 1. Axial FLAIR image (A) shows increased signal intensity in the splenium of the corpus callosum and in the right posterior temporal lobe, rapidly increasing after a 4 week period (B).

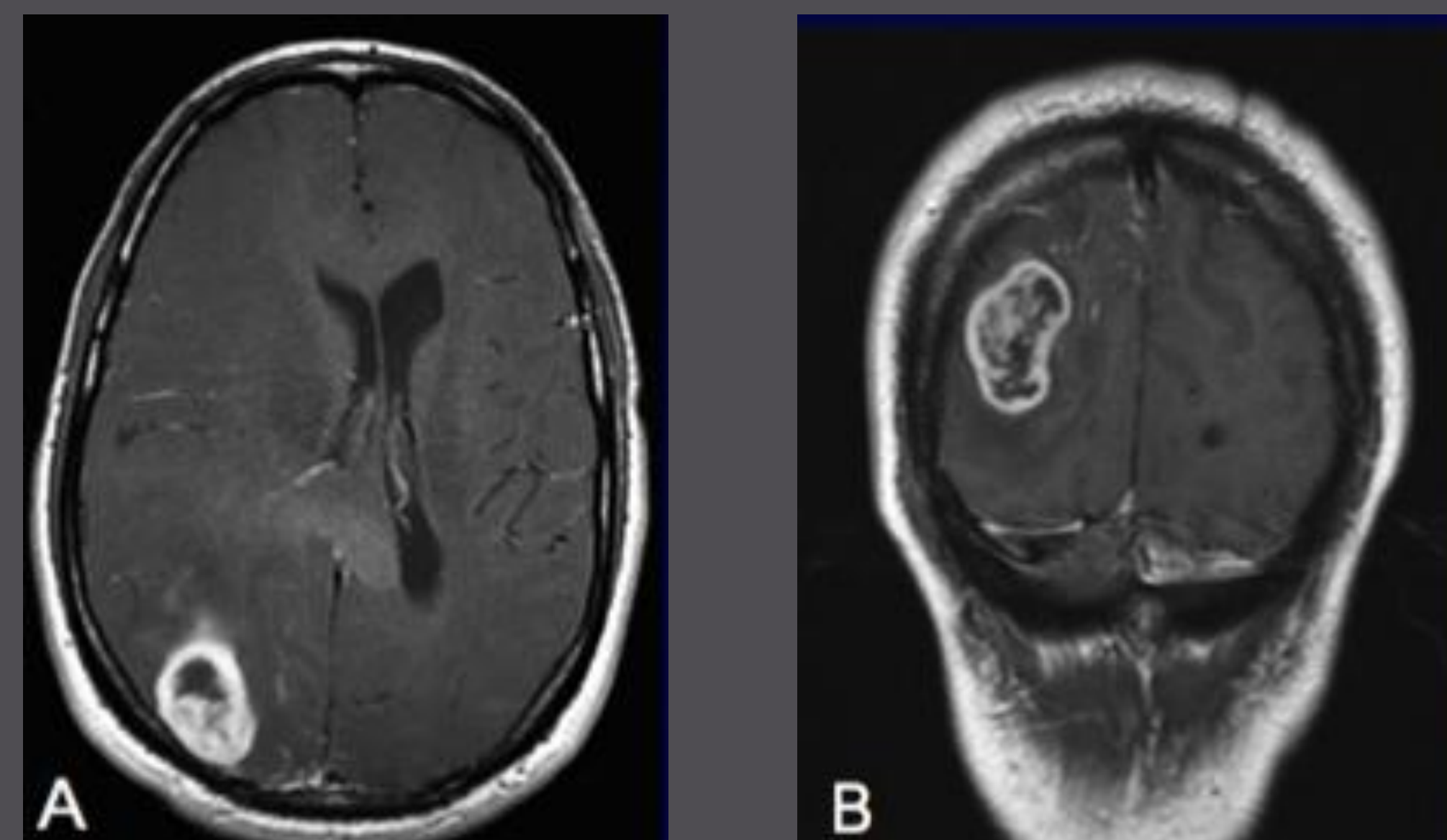


Figure 2. Contrast enhanced axial T₁ (A) and coronal T₁ (B) weighted images show irregular enhancement of the lesion. Fig 2A demonstrates the lesion abutting the dural surface characteristic of gliosarcoma.

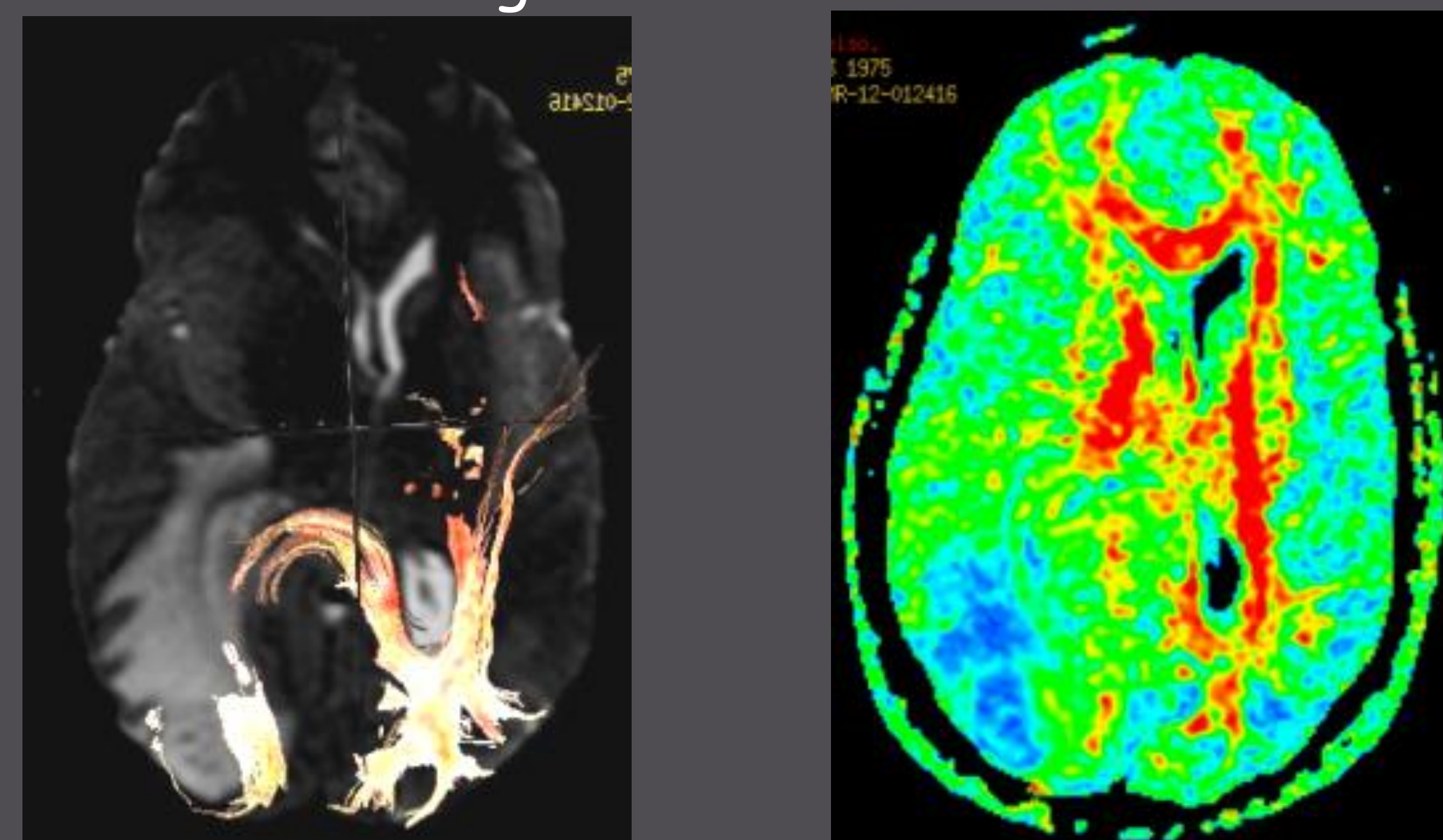


Figure 3. Diffusion tensor tractography shows marked destruction of white matter tracts compatible with destruction rather than invasion of parenchyma.

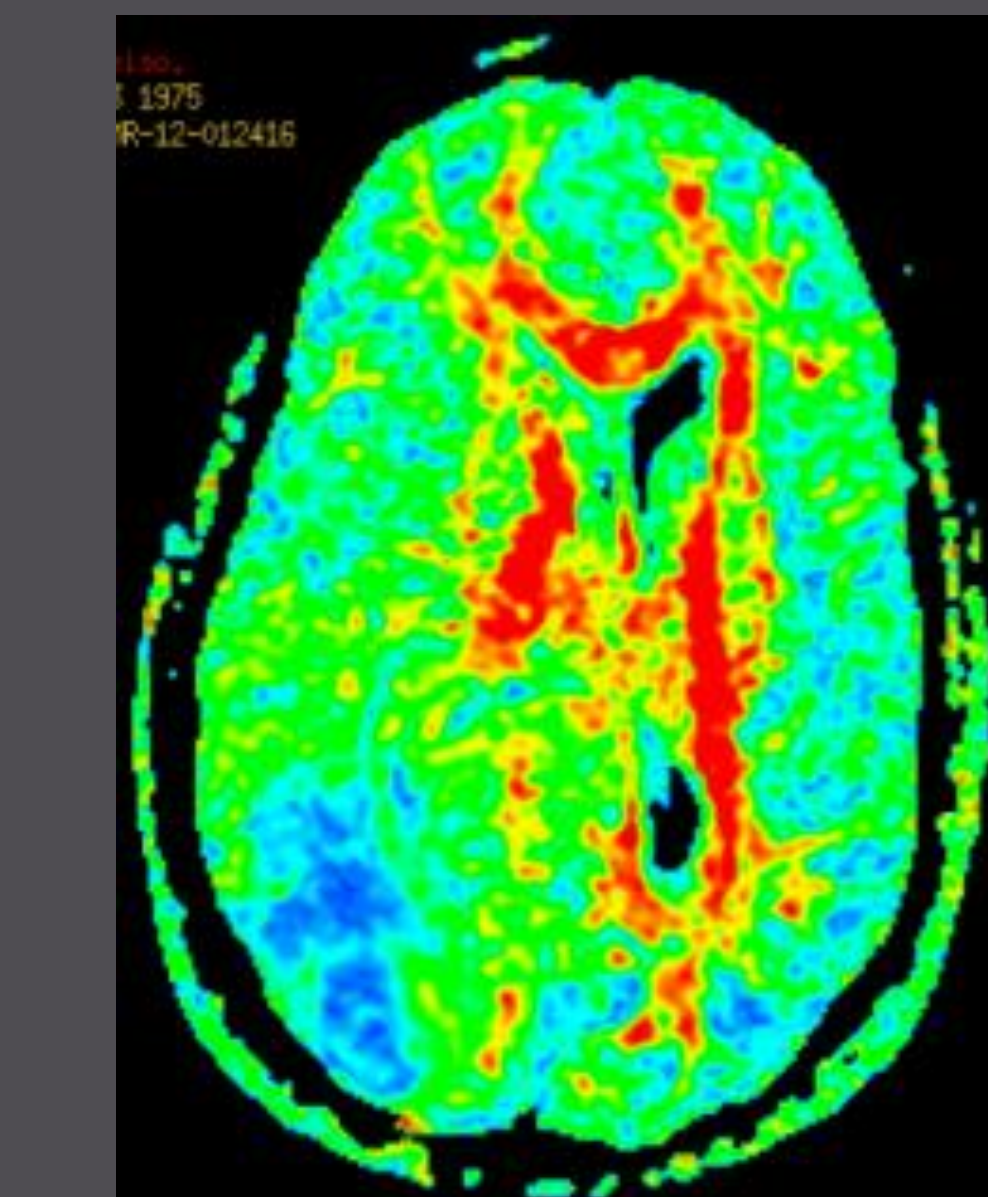


Figure 4. Fractional anisotropy is markedly reduced at the tumor site suggesting an aggressive and invasive lesion.

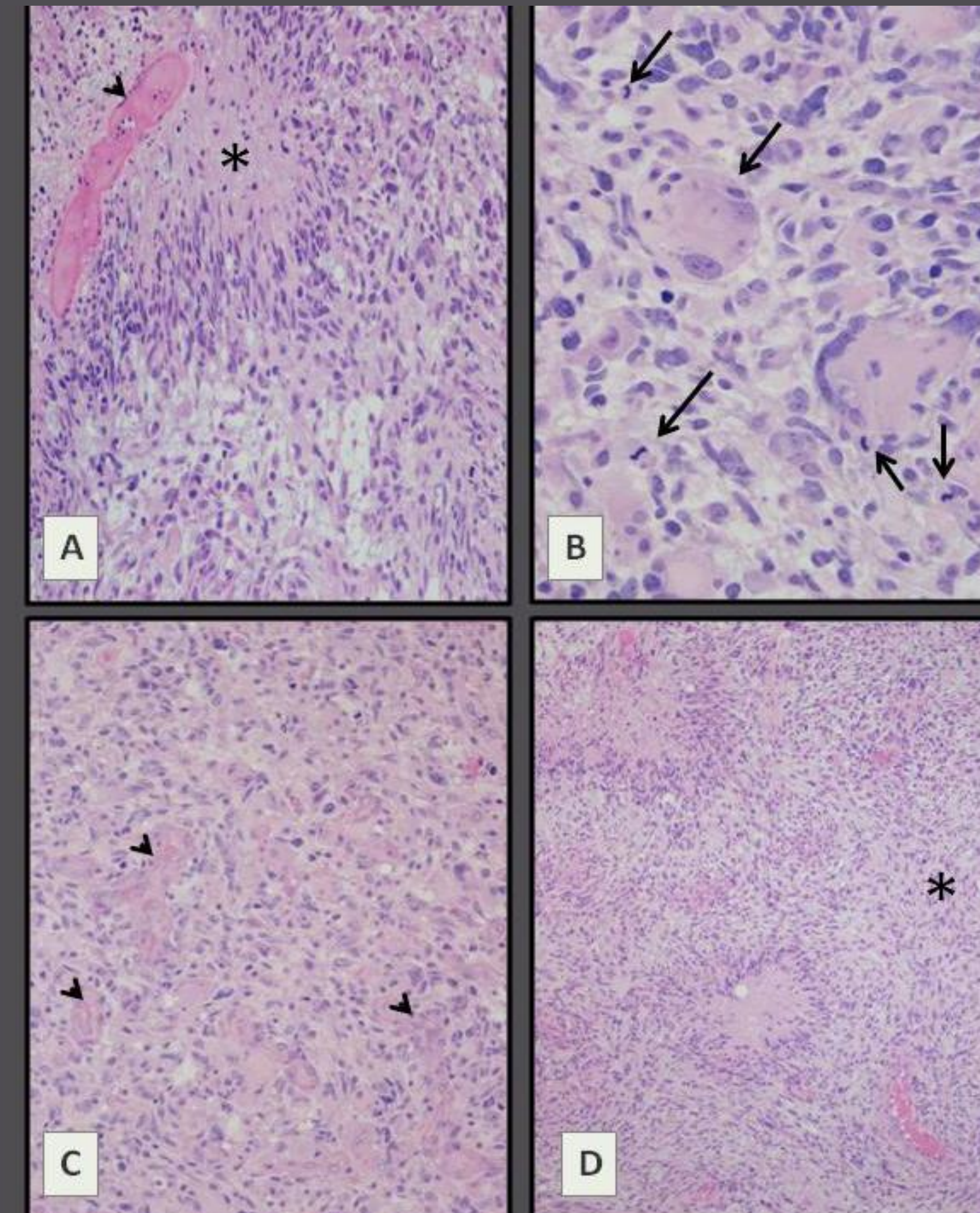


Figure 5. A: Palisading necrosis(asterisk), vascular thrombosis (arrow head). B: pleomorphism and increased mitotic activity (arrows).C: prominent vascular proliferation(arrow heads).D: Spindle sarcomatoid-like area (asterisk) associated with palisading necrosis. (A,B,C: H&E x 200, D: H&E x 100)

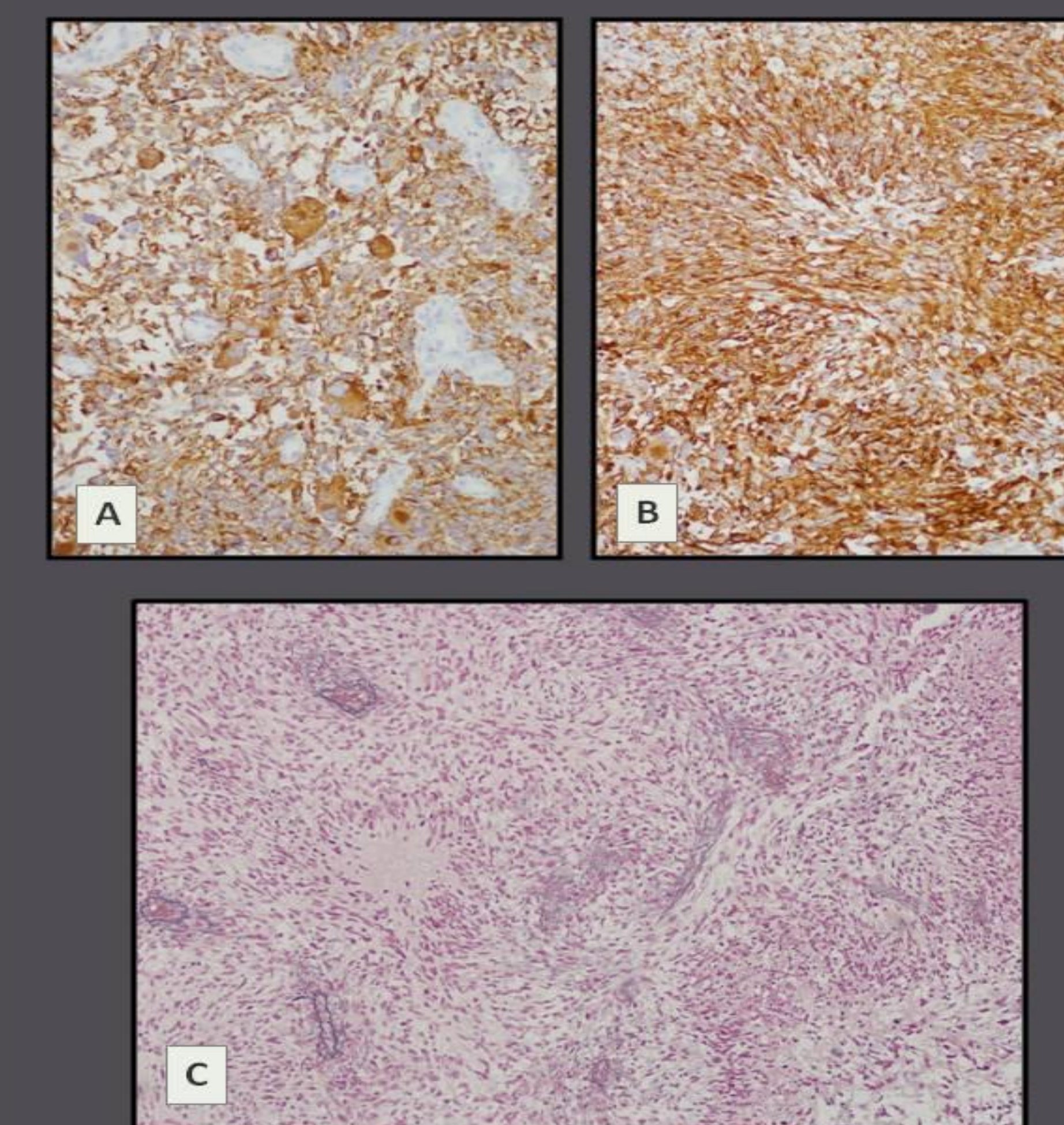


Figure 6. GFAP immunohistochemical stain show positivity in both classic (A) and sarcomatoid areas (B). Reticulin stain (C) highlights perivascular areas only. Sarcomatoid area is devoid of reticulin. Findings argue against the diagnosis of Gliosarcomatous variant of a Glioblastoma. (A,B: GFAP x 200; C: Reticulin x 100)

Results

- Patient had a series of conventional brain MRI scans showing rapid growth of a ring -enhancing lesion measuring 3.1x2.2x3.1 cm at the junction of the right parieto-occipital region.
- Extensive surrounding edema causing complete effacement of the posterior horn of the right lateral ventricle, parietal effacement of the anterior floor of the right ventricle, and a 1.2 cm right to left midline shift were observed.
- Mild diffuse enhancement in the region of the splenium of the corpus callosum were most likely compatible with seizure activity.
- Diffusion tensor showed marked decrease in anisotropy and destruction of fiber tracts likely demonstrating a more aggressive tumor.
- Spectroscopy showed evidence of tumor.
- MRA demonstrated 2 abnormal areas of signal intensity in the right occipital lobe in the splenium of the left corpus callosum
- Histopathology showed Glioblastoma, WHO grade IV (Fig. 5). Despite the radiologic suggestion of gliosarcoma and the presence of sarcomatous-like areas by hematoxylin and eosin (Fig. 5), immunohistochemical and special stains failed to confirm gliosarcoma (Fig.6)
- The patient and was placed on adjuvant radiation therapy with concurrent chemotherapy after gross total tumor resection.

Conclusion

Although glioblastoma and inflammatory disease are a differential diagnosis, radiological presentation using Diffusion Tensor Imaging and spectroscopy help to differentiate this case of glioblastoma from inflammatory disease. We report an unusual case of glioblastoma occupying the right parieto-occipital region of the brain.

References:

- Pakos, E E (09/2005). "Multi-focal gliosarcoma: a case report and review of the literature". *Journal of neuro-oncology* (0167-594X), 74 (3), 301.
- Han, Seunggu J (02/2010). "Primary gliosarcoma: key clinical and pathologic distinctions from glioblastoma with implications as a unique oncologic entity". *Journal of neuro-oncology* (0167-594X), 96 (3), 313.